

ORIGINAL ARTICLE

A randomized trial of the Vein Viewer versus standard technique for placement of peripherally inserted central catheters (PICCs) in neonates

K Phipps, A Modic, MA O’Riordan and M Walsh

Division of Neonatology, Department of Pediatrics, Rainbow Babies and Children’s Hospital, University Hospitals of Cleveland Case Medical Center, Cleveland, OH, USA

Objective: Peripherally inserted central catheters are important but can be difficult to place in neonates. Therefore, we compared a near-infrared device, the Vein Viewer, to determine if its use would increase successful line placement, with standard techniques.

Study Design: Randomized controlled trial in preterm and term neonates in a level 3 Neonatal Intensive Care Unit.

Result: In all, 115 subjects were enrolled with 59 randomized to the Vein Viewer group and 56 to the control group. Overall, use of the Vein Viewer showed a trend to more successful placement 86 versus 75%; unadjusted odds ratio 2.33 (0.90, 6.04; $P = 0.08$). Infants randomized to the Vein Viewer were more mature (30 ± 2 weeks gestational age (GA) versus 28 ± 2 weeks GA; $P = 0.08$). After adjusting for GA, use of the Vein Viewer was significantly more likely to lead to successful line placement (adjusted odds ratio 3.05 (1.10, 1.82)).

Conclusion: The Vein Viewer improved successful placement with the most benefit seen in infants of greater GA.

Journal of Perinatology advance online publication, 22 September 2011; doi:10.1038/jp.2011.129

Keywords: vascular access; vein visualization technology; newborn; successful venipuncture; venous catheterization

placement generally has been by visualization and palpation. In recent years, several technologies have been developed to aid placement. Venographic guidance utilizes contrast agents to radiographically visualize a vein. This requires a peripheral IV and may damage a prospective vein for PICC use.⁴ Ultrasound allows visualization without exposure to radiation but specialized training is needed which has limited its use.^{5,6} A transilluminator^{7,8} allows visualization of veins; its efficacy may be limited by the size of the infant. New to the list of choices to improve successful PICC placement is the Vein Viewer a Food and Drug Administration (2005) approved device (Figure 1). It is a non-invasive means of visualizing veins for possible line placement. The Vein Viewer patented snowflake technology was originally developed for the armed forces to use in the field for IV placement in critically wounded soldiers.⁹ The Vein Viewer utilizes a near-infrared light source to image the hemoglobin in red blood cells, allowing image processing technology to project a picture on top of the skin (Figure 2).⁹ This technology has shown improved first attempt venipuncture success in the pediatric population.¹⁰ To our knowledge, there are no published studies in neonates. Thus, we designed a randomized controlled trial to test the Vein Viewer against standard visualization and palpation in neonates for PICC placement.

Introduction

In tiny neonates, central intravenous access is essential and technically challenging. Peripheral intravenous cannulas are not feasible for long duration access needed in tiny preterm neonates.¹ Peripherally inserted central catheters (PICCs) have emerged as the standard of care.^{2–4} In neonates, the success of PICC placement is affected by many factors including skin condition, illness, patient weight, vein condition and visibility.¹ Selection of veins for PICC

Methods

One hundred twenty neonates ($77 < 1500$ g and $43 \geq 1500$ g) who were chosen for PICC placement by the clinical team at Rainbow Babies and Children’s Hospital from August 2007 to February 2009 were enrolled. Following informed consent, patients were randomized using a computer generated random number schema in blocks of 10 with sealed opaque envelopes. Infants randomized to control had placement using standard techniques including vein visualization, palpation and transillumination. Infants randomized to the experimental group had placement augmented by use of the Vein Viewer using the manufacturer’s recommended techniques. To insure optimal alignment of the vasculature with the projected

Correspondence: K Phipps, Division of Neonatology, Department of Pediatrics, Rainbow Babies and Children’s Hospital, University Hospitals of Cleveland Case Medical Center, 11100 Euclid Avenue, Cleveland, OH 44106-6010, USA.
E-mail: karla.phipps@UHhospitals.org
Received 13 May 2011; revised 3 August 2011; accepted 4 August 2011

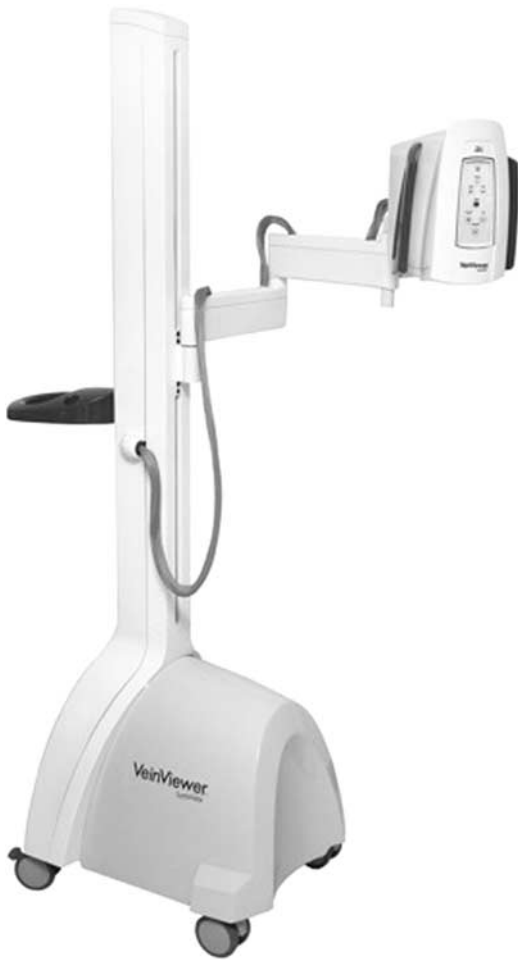

Figure 1 Vein Viewer imaging system.

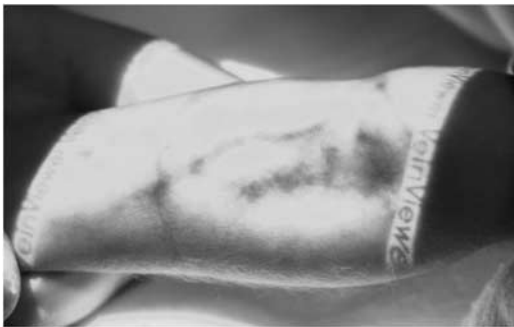

Figure 2 Vein Viewer image of a neonatal arm.

image, the Vein Viewer was calibrated before each use. It was then placed over the extremity of choice at a 90° angle; a near-infrared augmented image was obtained (Figure 3).⁹

Other than the visualization technique used, all other aspects of placement were performed using institutional standards. Accordingly, all lines were placed by an expert level neonatal nurse practitioner/registered nurse PICC team, in-serviced by the manufacturer's representative on the use of the Vein Viewer. Infants in both groups had placement performed under sterile

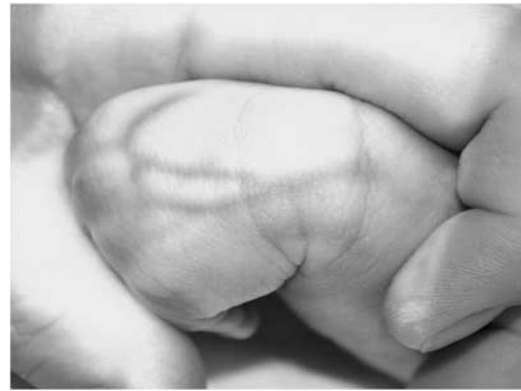

Figure 3 Vein Viewer image of a neonatal hand.

conditions with maximal barrier precautions. The most appropriate vessel was chosen for line insertion, whether by direct visualization or Vein Viewer image.

By institutional policy, each session was limited to four attempts per session, with a maximum of three sessions. If PICC placement failed at any session, the clinical team determined whether additional attempts were warranted. Successful placement was defined as vessel entry and radiographic confirmation of central location of the catheter tip.^{1,6,11}

Demographic descriptors, clinical care variables and factors possibly influencing successful placement (including number of previous intravenous placements, hematocrit, bilirubin level and hydration status) were collected.

Sample size and analytic techniques

Nominal variables are described as frequencies with mean values and s.d. or medians and ranges for continuous measures. Nominal variables were compared using χ^2 analysis or Fischer's exact test as appropriate, while continuous variables were compared with two sample tests (*t*-tests or Wilcoxon's rank sum tests). Logistic regression analyses were used to adjust for group and gestational age (GA). All analyses were performed using intention to treat. Significance was set at $P = 0.05$.

Sample size calculations were performed *a priori*. We calculated that a total of 115 subjects would be needed to detect a 50% improvement in the success rate from a baseline 50% with the standard technique to 75% with the Vein Viewer with an α of 0.05 and a power of 80%.

Results

After randomization, five patients (three control and two Vein Viewer) were withdrawn due to change in medical plan that did not include PICC placement. Patient demographics with regard to GA, birth-weight, race or gender were similar for the Vein Viewer and control groups (Table 1). Clinical characteristics were gathered within 48 h of PICC insertion. These included hematocrit, sodium,

Table 1 Baseline characteristics

	Standard (N = 56)	Vein Viewer (N = 59)	P
Gestational age (weeks)	28.0 (23–40)	30.0 (23–40)	0.08
Birthweight (g)	1030 (320–4160)	1160 (300–4700)	0.06
Gender, male, N (%)	35 (62.5)	32 (54.2)	0.37
African American, N (%)	29 (51.8)	27 (45.8)	0.52
Hematocrit (%)	39.0 (28–60)	42.0 (28–62)	0.03
Sodium (mEq)	141 (126–155)	139 (129–151)	0.04
Potassium	4.0 (2.7–6.5)	4.5 (3–6)	0.19
FiO ₂ (%)	0.24 (0.21–0.80)	0.21 (0.18–0.98)	0.49
Platelets (100 000)	213 (53–454)	205 (53–388)	0.67
Total serum bilirubin (mg dl ⁻¹)	5.45 (0.10–14.70)	5.65 (0.00–13.5)	0.82

Median and range unless otherwise specified.

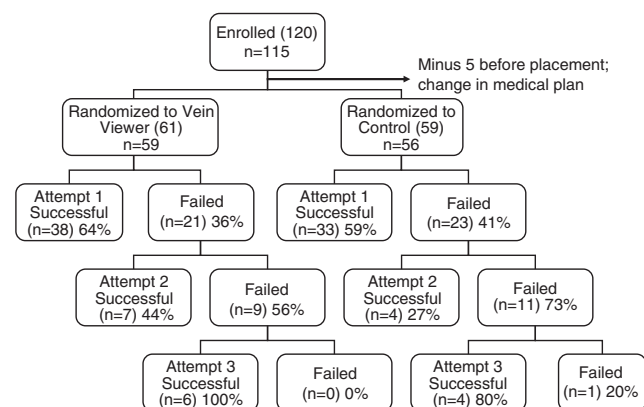
FiO₂ at time of placement, platelet count, potassium and total serum bilirubin. The values were similar in both groups. Of note, hematocrit was significantly higher ($P = 0.03$) and sodium significantly lower ($P = 0.04$) in the Vein Viewer group. It is unclear if these differences are clinically meaningful.

Use of the Vein Viewer led to a higher rate of successful PICC placement compared with standard techniques. Overall success (86% Vein Viewer versus 75% control group; $P = 0.08$) is not statistically significant, but it is clinically meaningful. Figure 4 shows the progression of subjects through a series of placement attempts.

When analysis is limited to the first session, no differences between the two techniques were found. PICC lines were successfully placed on the first attempt in 64% of those in the Vein Viewer and 59% in the control group ($P = 0.55$). Per study protocol, decisions about additional sessions were made by the clinical team, which elected to defer additional attempts in 5 Vein Viewer and 8 control patients after one failed session (13 total patients).

After two sessions, an additional 7 of 16 (44%) in the Vein Viewer and 4 of 15 (27%) in the control group were successful ($P = 0.32$). Placement was again deferred on three Vein Viewer and six control patients after two failed sessions (nine patients). In the third session, 3 of 3 (100%) in the Vein Viewer and 4 of 5 (80%) in the control group had successful placement ($P = 0.25$).

We analyzed factors possibly associated with successful placement. We found that patient GA significantly influenced the likelihood of success. Those that achieved success on the first attempt, regardless of group, had a significantly lower GA (28.8 ± 4.3 weeks compared with 31.2 ± 5.1 weeks, $P = 0.008$). The results were consistent for those achieving overall success (29.5 ± 4.7 weeks compared with 31.6 ± 4.8 weeks, $P = 0.04$). Because of the differences in GA, logistic regression adjusting for GA between groups was done on all subjects for all PICC sessions.

**Figure 4** Flow of patients through peripherally inserted central catheter (PICC) placement attempts by group.**Table 2** Adjusted odds ratio

	Unadjusted odds ratio (95% CI)	Adjusted odds ratio (95% CI)
Success on first attempt	1.26 (0.59, 2.68)	1.57 (0.71, 3.50)
Any success	2.33 (0.90, 6.04)	3.05 (1.10, 8.42)

Abbreviation: CI, confidence interval.

The Vein Viewer significantly improved overall successful placement (unadjusted odds ratio 2.33 (0.90, 6.04); adjusted odds ratio 3.05 (1.1, 8.42); Table 2).

Discussion

To our knowledge, this is the first randomized trial to evaluate the efficacy of the Vein Viewer in improving successful PICC placement in neonates. Use of the Vein Viewer was associated with a trend toward more successful placement ($P = 0.08$). The benefit was most clearly seen in more mature infants in whom visualization of vessels is the most challenging. We speculate that the use of the Vein Viewer did not benefit smaller preterm infants because their translucent skin provides easy visualization of vessels.

The overall success rate for PICC placement in this study was 75% using standard techniques. It is possible that the control group's higher success rate in this study compromised our ability to detect statistically significant benefits of the Vein Viewer. Other centers with a lower success rate might find the Vein Viewer more beneficial.

One limitation to our study is the lack of ability to mask the intervention: those placing the lines clearly could distinguish which was used. However, the outcome assessment defined by radiograph was performed by radiologists masked to the assignment, which minimizes potential bias in outcome ascertainment. Use of the Vein Viewer identifies a neonate's

individual vascular pattern that may not be seen by standard techniques. It identifies those veins that may have been previously damaged in prior insertion attempts.

The team may have been biased against further attempts at line placement by these visual findings with the Vein Viewer. Limitation of attempts, unlikely to succeed prevents needless sticks and pain associated with further attempts, thus a net clinical benefit.

The Vein Viewer used in this study was a large device (height 60 inches and weight 20 pounds), stored in a central location rather than in the Neonatal Intensive Care Unit, and brought to the subject's bedside for use. This may have decreased staff enthusiasm for its use in subtle ways. Institutions that have a dedicated device on the unit might show greater use. Newer generations of this imaging technology are smaller and may be associated with better staff utilization. All of these factors may influence success or failure of line placement.

According to a recent study published in Pediatric Emergency Care January 2011, a magnification effect making veins appear larger than actual size was discovered by the manufacturer. This may have affected our success in the smaller neonates. With accurate magnification in the newer device and proper identification of vein size; a smaller gauge catheter could have been used and improved success.¹²

In summary, the Vein Viewer is a useful device for enhancing PICC placement, particularly among older, more mature neonates whose vasculature is more difficult to detect visually. It provides possibilities for placement in areas not otherwise likely to be chosen as well as the avoidance of placement attempts in damaged veins. The use of new imaging technology is an important adjunct in the Neonatal Intensive Care Unit to improve first stick PICC placement and vein salvation. Further studies using imaging technology are

needed to evaluate the benefits of a smaller, more easily accessible device with a focus on larger more mature infants.

Conflict of interest

The authors declare no conflict of interest.

References

- 1 Pettit J, Mason-Wyckoff M. *Peripherally Inserted Central Catheters: Guidelines for Practice*. National Association of Neonatal Nurses: Glenview, IL, 2001.
- 2 Evans M, Lentsch D. Percutaneously inserted polyurethane central catheters in the NICU: one unit's experience. *Neonatal Netw* 1999; **18**(6): 37–46.
- 3 Burns D. The Vanderbilt PICC Service: program, procedural and patient outcomes successes. *J Assoc Vasc Access* 2005; **10**(4): 1–9.
- 4 Crowley JJ. Vascular access. *Tech Vasc Interv Radiol* 2003; **6**(4): 176–181.
- 5 Andreatta P, Chen Y, Marsh M, Cho K. Simulation-based training improves applied clinical placement of ultrasound-guided PICCs. *Support Care Cancer* 2011; **19**(4): 539–543.
- 6 Infusion Nurses Society. Peripherally inserted central catheters: position statement. *J Infus Nurs* 2006; **20**: 172–174.
- 7 Pettit J. Technological advances for PICC placement and management. *Adv Neonatal Care* 2007; **7**(3): 122–131.
- 8 Goren A, Laufer J, Yativ N, Kuint J, Ackon M, Rubinshtein M *et al*. Transillumination of the palm for venipuncture in infants. *Pediatr Emerg Care* 2001; **17**(2): 130–131.
- 9 Christie Medical Holdings. VeinViewer Vision (Internet), 2011 (cited 2011 Aug 3). Available from <http://www.christiedigital.com/en-us/medical/products/veinviewer-vision-vascular-access/pages/default.aspx>.
- 10 Hess H. A biomedical device to improve pediatric vascular access success. *Pediatr Nurs* 2010; **36**(5): 259–263.
- 11 Infusion Nurses Society. Infusion nursing specialty practice. *J Infus Nurs* 2006; **29**(1): S1–S92.
- 12 Perry A, Caviness A, Hsu D. Efficacy of a near-infrared light device in pediatric intravenous cannulation. *Pediatr Emerg Care* 2011; **27**(1): 5–10.